



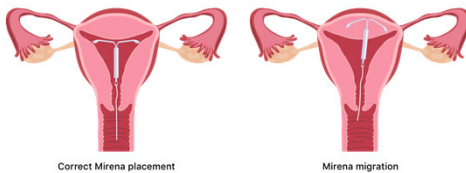
Case of the 11-year Missing IUD: Incidental finding of Migrated Intra-Uterine Device during Elective Robotic-Assist Laparoscopic Hysterectomy

Sterling, MD. Chambers, MD. Lake, MD.



Background/Introduction

Intra-uterine devices have been considered a first-line option for reversible contraception with >99% effective rate of preventing pregnancy. Over 14% of women who use a form of contraception use a long-acting reversible contraception like IUDs. Complications include infection, non-visualized strings, expulsion, and perforation. Migration of IUDs through the uterine wall is an infrequent complication with a reported incidence between 1.3 and 1.6 per 1000 placed. This report describes the incidental finding, removal, and management of a migrated IUD causing serosal injury to the rectum during elective robot-assist laparoscopic hysterectomy.



Abstract

Migration of Intra-uterine devices (IUDs) is a rare, yet serious complication associated with a well-accepted means of contraception. IUDs have long been a safe and effect option for women of child-bearing age to prevent pregnancy. We present a 48-year-old female with known symptomatic uterine fibroids undergoing a robot-assist laparoscopic hysterectomy in the elective setting found to have a previously placed IUD that migrated through her uterus and was adherent and invading into her rectum. This IUD was removed without complication and without perforation of bowel. Surgical retrieval of IUD perforation should always be considered, whether symptomatic or not, to prevent serious complication. Laparoscopic removal is the option of choice, but laparotomy may be required.

Case Report

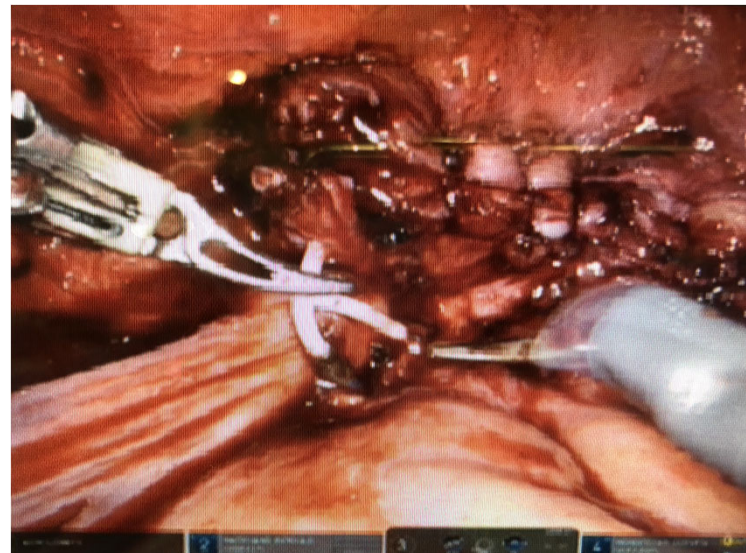A 48-year-old Caucasian female with history of symptomatic uterine fibroids presented for elective total abdominal hysterectomy with bilateral salpingectomy. She is G2P0-0-2-0 (AB x2) with worsening menorrhagia and dysmenorrhea described as extremely heavy and painful. She has no history of uterine masses or family history of gynecologic malignancy. Prior pelvic ultrasonography was significant for uterine leiomyoma, but no IUD was detected. An IUD had been placed eleven years prior and was presumed to be lost at an unknown time.

During standard dissection of the left broad ligament of the uterus using a da Vinci Xii robot, strings of an IUD were identified. The IUD was identified fully expelled through the uterus in the cul-de-sac and embedded into the serosa of the adjacent rectum. Extensive endometriosis was noted within the pelvis including involvement of bilateral ovaries and in the cul-de-sac. Robot-assist laparoscopic hysterectomy was completed with excision of endometriosis and bilateral salpingo-oophorectomy. Intraoperative consultation to General Surgery was performed. The patient was placed in the left lateral decubitus position, the anal region was examined, a rectal exam was performed, the sigmoidoscope was inserted and advanced without difficulty to a distance of 25 cm. The IUD was removed laparoscopically. A leak test was performed to assess for perforation which was not seen. The area of concern was inspected closely, and there was a small area of erosion or pressure injury to the serosa which was repaired with 3.0 vicryl suture in a simple interrupted fashion. Another leak test was performed, and no leak was observed. No evidence of rectal perforation was observed. The procedure was completed, the patient was extubated and was taken to the post-operative area in stable condition.

The patient was admitted to the hospital for close observation and intravenous antibiotics. Diet was advanced on post-operative day one. The patient remained afebrile without concerning findings of bowel perforation including normal white blood cell count, benign abdominal exam, and normal passage of flatus and bowel movement. She was discharged on post-operative day two with a regular diet and a 5-day course of oral ciprofloxacin and metronidazole.

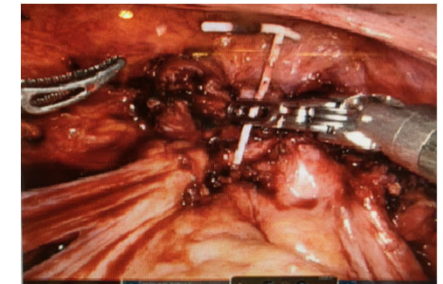
She was seen in clinic on post-operative day twenty-six and was fully recovered. Colonoscopy was planned for 6-8 weeks.

Intra-Operative Finding



Discussion

Intra-uterine device migration is a rare, but potentially serious complication associated with this reversible contraception method. Incidentally found foreign bodies should be removed urgently before bowel, urinary bladder, or other organ penetration occurs. Although this patient did not experience an adverse outcome associated with this rare complication, morbidity does occur.



References

- Li R, Li H, Zhang J, Li H. Rectum migration of an intrauterine device. *J Minim Access Surg.* 2021;17(1):113-115. doi:10.4103/jmas.JMAS_268_19
- Ye H, Huang S, Zhou Q, et al. Migration of a foreign body to the rectum: A case report and literature review. *Medicine (Baltimore).* 2018;97(28):e11512. doi:10.1097/MD.00000000000011512
- Ma GW, Yuen A, Vlachou PA, de Montbrun S. An unconventional therapeutic approach to a migratory IUD causing perforation of the rectum. *J Surg Case Rep.* 2016;2016(2):rjw004. Published 2016 Feb 2. doi:10.1093/jscr/rjw004
- DiPaola L, Wonaga A, Dardanelli M, Viola L. Intrauterine device in the rectal cavity. *Rev Esp Enferm Dig.* 2017;109(4):290.
- Han X, Yang H. Successful endoscopic management of 3 cases of translocated intrauterine devices: a case report. *Ann Palliat Med.* 2021;10(2):2371-2378. doi:10.21037/apm-21-184
- Medina TM, Hill DA, DeJesus S, Hoover F. IUD removal with colonoscopy: a case report. *J Reprod Med.* 2005;50(7):547-549.
- Shute L, Pidutti J, Trepman E, Burnett M, Embil JM. Rectal Perforation by an Intrauterine Device Leading to Fatal Intra-Abdominal Sepsis and Necrotizing Fasciitis. *J Obstet Gynaecol Can.* 2021;43(6):760-762. doi:10.1016/j.jogc.2020.09.015
- Al Sahaf MA, Bseiso BF, Al-Momen SA, Meshikhes AN. Endoscopic removal of an incidentally discovered intrauterine contraceptive device eroding into the rectum. *BMJ Case Rep.* 2019;12(9):e231410. Published 2019 Sep 12. doi:10.1136/bcr-2019-231410